

## Original Article

# Nocardiosis in some ornamental fishes in Iran

Najmeh Sheikhzadeh<sup>1\*</sup>, Tayebeh Fakheri<sup>1</sup>, Katayoon Nofouzi<sup>2</sup>

1-Department of Food Hygiene and Aquatic Animals, Faculty of Veterinary Medicine, University of Tabriz, Tabriz, Iran

2-Department of Pathobiology, Faculty of Veterinary Medicine, University of Tabriz, Tabriz, Iran

\*Corresponding Author: [nsheikh@tabrizu.ac.ir](mailto:nsheikh@tabrizu.ac.ir)

(Received 4 August 2019, Accepted 26 September 2019)

## Summary

Nocardiosis is a systemic disease in fish in which lesions are frequently localized in the integument and several internal organs, with the nodular lesions characteristic of granulomata. The zoonotic species of *Nocardia* (*N. asteroides*) is a pathogen of humans and many animals. Considering the lack of information about the status of *Nocardia* species in fish species in Iran, the widespread use of aquariums, and possible transmission of zoonotic diseases from ornamental fishes to human, primary study for detecting this bacterium was performed. In this study, 100 freshwater aquarium fishes (apparently healthy and unhealthy) were purchased from some shops located in Tehran, Tabriz, Zanjan, and Shahindej cities completely randomly and transferred to the laboratory. Fish samples were examined for the *Nocardia* genus and *N. asteroides* using nested polymerase chain reaction (PCR) assay. In the macroscopic examination, no granulomatous lesions were detected. PCR examination showed that one healthy fish and three sick fish (with clamped fin, lethargy, and slow-motion sings) were infected by *Nocardia*. But PCR amplification of *N. asteroides* by specific primers did not amplify DNA gyrase gene sequences of *N. asteroides*. This study is the first known identification of *Nocardia* -infected ornamental fishes in Iran.

**Keywords:** Nocardiosis, *N. asteroides*, Aquarium fishes, PCR.

## Introduction

Nocardiosis is well known as a systemic bacterial infection caused by a Gram-positive, partially acid-fast, aerobic, and

filamentous bacterium in farmed, and ornamental freshwater and marine fishes (Wang et al., 2007). The clinical signs of this disease are sluggish or flashing behavior, emaciation, exophthalmia, and distended abdomen. In later stages, nodular and diffuse

granulomatous lesions can be found in skeletal muscle, gills, and any of the visceral organs (Lee et al., 2007).

Three species of *Nocardia* including *Nocardia salmonicida*, *N. seriolae* (formerly *N. kampachi*), and *N. asteroides* have been previously identified from diseased fish. *N. asteroides*, one of the most virulent species, has been detected from humans, cats, dogs, goats, cattle, marine mammals, and fishes (Chen et al., 2000). In humans, clinical forms consist of pulmonary implication, skin or soft tissue involvement, and diffused forms with the brain and pulmonary infections. Primary nocardial infection presents by pulmonary or cutaneous and/or subcutaneous lesions. Disseminated disease is determined by the detection of nocardial infection in two or more organs. The lung is the most frequently implicated organ, followed by skin and brain. Of note, nocardiosis has been demonstrated in human receiving immunosuppressive therapy, subjects with chronic pulmonary diseases, organ transplant recipients, and patients infected with the human immunodeficiency virus (HIV) (Corti and Fiotti, 2003).

Because of the zoonotic character of nocardial infection, enhancing importance of aquariology, and lack of any information about the presence of Nocardiosis in fish

species in Iran, the present study was undertaken to detect *Nocardia* genus and zoonotic *N. asteroides* in diseased and clinically healthy ornamental fish by polymerase chain reaction (PCR) assay.

## Materials and methods

### *Fish sampling*

One hundred freshwater aquarium fishes of 22 species were examined from April to September 2010. These fishes were purchased from some local shops in four cities in Iran (including Tehran, Tabriz, Zanjan, and Shahindezh). Among 100 fish, 22 samples were apparently healthy.

Seventy-eight moribund fish with clinical signs including emaciation, clamped fin, fin rot, lethargy, and anorexia were selected. Live fishes were transported in oxygenated insulated coolers to the bacteriology laboratory of veterinary faculty, University of Tabriz. Live fishes were killed by immersion in clove oil (50  $\mu\text{L L}^{-1}$ ).

### *PCR assay*

DNA was extracted from internal organs, including the digestive system and kidney using isopropanol method, according to the manufacturer's instructions. Extracted DNA was verified by electrophoresis on 1% agarose gel. The concentration and purity of DNA was assessed with a NanoDrop

spectrophotometer (Thermo Fisher Scientific™).

Gene encoding *16S ribosomal RNA* was used as a target gene in *Nocardia* identification. NO1 and NO2 primers were conducted according to the published sequences of the genes (Accession No JX484797.1). Gene encoding DNA gyrase subtype B was used to detect *N.asteroides*. NAD1 and NAD2 primers were designed according to the published sequences of the genes (Accession No JN041222.1). Primer synthesis was performed by Bioneer Company (Korea).

The PCR was conducted by Master Cycler Gradient-Eppendorf (Germany). The PCR

reagents included 1 µL of each primer, 1 µL of extracted DNA, 12.5 µL of master mix (consisting buffer, MgCl<sub>2</sub>, dNTP, Taq DNA polymerase) with a final volume of 25 µL. The PCR thermal cycling parameters were: 1 cycle at 95°C for 1 min, 35 cycles by 94°C for 60s, 57°C for 60s and 72°C for 60s followed with final extension for 10 min at 72°C. The sequences of the primers used in this study are displayed in Table 1. Amplicons were analyzed by the agarose gel electrophoresis, stained with fluoro dye, visualized under UV light, and photographed at final with 700 and 406-bp for identification of *Nocardia* and *N. asteroides*, respectively.

**Table 1.** Characteristics and sequences of PCR primers for *Nocardia* detection.

Target gene	Primer sequence	Accession no.	Product length
<i>Nocardia</i>	F: 5'-CAGCTTGTTGGTGGGGTAATG-3' R: 5'-GAATTAATCCACATGCTCCGC'-3'	JX484797.1	700 (bp)
<i>Nocardia asteroides</i>	F: 5'-GGTGACGATATCCGCGAGGG-3' R: 5'-GCAGCGGCAGGATCGCCT-3'	JN041222.1	406 (bp)

## Results

In this study, the *Nocardia* genus was detected in diseased and apparently healthy ornamental fish by polymerase chain reaction (PCR) assay.

Results of the PCR reaction for *16S ribosomal RNA* of sampled fishes are shown in Fig. 1. Four out of 100 extracted DNA for

*16S ribosomal RNA* genes were *Nocardia* positive. Identification for DNA gyrase B subunit gene of *N. asteroides* was also performed that no positive sample was found.

Among four fish samples infected with *Nocardia*, one green neon tetra (*Paracheirodon simulans*) was apparently healthy. In contrast, three remaining

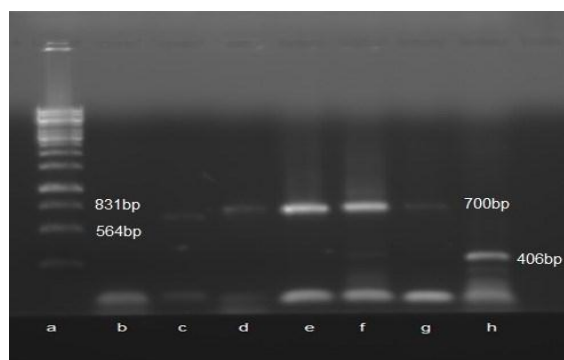
infected fishes, including one shark (*Myxocyprinus asiaticus*), one oscar (*Astronotus ocellatus*) and one goldfish (*Carassius auratus*) showed some signs of the clamped fin, lethargy, and slow motion. However, no macroscopic nodules were seen in fish samples.

### Discussion

Nocardiosis was frequently observed in the aquarium industry in recent years (Itano et al., 2006; Wang et al., 2009; Cornwell et al., 2011; Elkesh et al., 2013). In the present study, nocardiosis was found in some diseased and apparently healthy ornamental fishes in Iran; however, *N. asteroides* was negative by PCR method. Noteworthy, regarding the similar clinical signs and pathology with fish *Mycobacterium*, some mistakes in detection might happen. Therefore, some sensitive methods for differentiation are needed. PCR has higher sensitivity and specificity compared to the histological and bacteriological methods in fish nocardiosis diagnosis (Wang et al., 2014). In this regard, Alfaresi and Elkosh (2006) reported 90% sensitivity and 100% specificity for PCR. It commonly takes about two weeks for microbiological tests and antibiotic susceptibility assays for nocardiosis diagnosis, but real-time PCR

analysis of *16S rDNA* can be performed in a few hours (Alfaresi and Elkosh, 2006).

In previous studies, PCR was used for the identification of the *Nocardia* genus and species. For example, Itano et al (2006) found *N. seriolae* in some infected fishes by Loop-mediated isothermal amplification (LAMP) and PCR methods. In fact, LAMP could demonstrate *N. seriolae* in four unknown states of *N. seriolae* infectivity. However, PCR could identify only one sample from these fishes. According to literature, the identification of *N. seriolae* by LAMP is more sensitive than that of PCR, but the PCR method is still a sensitive way for *Nocardia* confirmation. In another study by Wang et al (2009), in cultured three striped tiger-fish, *Terapon jarbua*, with clinical signs including lethargy, hemorrhages, and ulcers on the skin, varying degrees of ascites associated with the enlargement of the spleen, liver, kidney, and obvious white nodules in these organs, *N. seriolae* was positive by PCR method. Meanwhile, Cornwell et al (2011) detected nocardial infection on cultured weakfish, *Cynoscion regalis* (Bloch and Schneider) using pathological and molecular analysis.



**Fig 1.** Gel electrophoresis demonstrating *Nocardia* DNA in fish samples by PCR, Lane a, molecular size markers. (DNA ladder); Lane b, negative control; Lane c, positive *Nocardia* sample (number 7), Lane d, positive *Nocardia* sample (number 21); Lane e, positive control for the standard strain of *Nocardia*; Lane f, positive *Nocardia* sample (number 74); Lane g, positive *Nocardia* sample (number 93); Lane h, positive control for the standard strain of *N. asteroides*

These researchers believed that *Nocardia* spp. are opportunistic infectious agents, and it is probable that the stress of capture and higher stocking density, coupled with the slightly raised levels of ammonia and nitrites in the system, allowed the infection to cause mortalities in cultured fishes (Cornwell et al., 2011). In recent years, some studies were mainly focused on the use of immunostimulants or efficient vaccines against *Nocardia*. For example, Kato et al. (2012) found that Japanese flounder (*Paralichthys olivaceus*) were partially protected against nocardiosis with Freund's complete adjuvant. Meanwhile, inactivated *N. seriolae* could increase the non-specific immunity of *Channa argus*, producing remarkable protection against the pathogen

bacteria (Xie et al., 2013). On the other hands, there was a significant protective impact for *Nocardia* infected *Channa argus* with the whole peptidoglycan from *N. seriolae* intraperitoneal injection more than 21 days (Peng et al., 2013). In recent studies, it was shown that Interleukin-12 and recombinant interferon gamma elicited effective protective immunity, which will help in development of a suitable vaccine and/or adjunct therapy against *N. seriolae* infection in fish (Nayak et al., 2014; Matsomoto et al., 2017).

In this study, detection of *Nocardia* in diseased ornamental fishes could have a similar reason to the previous study (Cornwell et al., 2011). On the other hand, identification of *Nocardia* in one healthy fish, green neon tetra, shows the low level of bacterial particles in the PCR method, which is an important point in disease transmission, especially in zoonotic *N.asteroids*.

In conclusion, the current study proved the presence of *Nocardia* in diseased and even apparently healthy aquarium fishes in Iran by PCR assay; however, zoonotic *N. asteroides* was not identified in similar fish samples. Considering *Nocardia* infection as an occupational hazard for certain professionals like pet shop workers and possible transmission of bacterium from

infected fishes to humans with the suppressed immune system, more attention is needed to recognize fish nocardiosis in different regions in Iran.

### Acknowledgments

The authors are grateful to the Research affairs of Tabriz University for financial support.

### References

- Alfaresi M. and Elkosh A. (2006). Rapid identification of clinically relevant *Nocardia* species using real-time PCR with syber green and melting-curve analysis. *Journal of Medical Microbiology*, 55, pp. 1711-1715.
- Chen S.C., Lee J.L., Lai C.C., Gu Y.W., Wang C.T., Chan, H.Y. and Tsai K.H. (2000). Nocardiosis in sea bass, *Lateolabrax japonicas*, in Taiwan. *Journal of Fish Disease*, 23, pp. 299-307.
- Cornwell E.R., Cinelli M.J., McIntosh D.M., Blank G.S., Wooster G.A., Grocock G.H., Getchell R.G. and Bowser P.R. (2011). Epizootic *Nocardia* infection in cultured weakfish, *Cynoscion regalis* (Bloch and Schneider). *Journal of Fish Diseases*, 34, pp. 567-571.
- Corti M.E. and Fioti M.F.V. (2003). Nocardiosis: a review. *International Journal of Infection Diseases*, 7, pp. 243-250.
- Elkesh A., Kantham K.P.L., Shinn A.P., Crumlish M. and Richard R.H. (2013). Systemic nocardiosis in a Mediterranean population of cultured meager, *Argyrosomus regius* Asso (*Perciformes: Sciaenidae*). *Journal of Fish Disease*, 36, pp. 141-149.
- Itano T., Hawakami H., Kono T. and Sakai M. (2006). Detection of fish nocardiosis by loop-mediated isothermal amplification. *Journal of Applied Microbiology*, 100, pp. 1381-1387.
- Kato G., Kondo H., Aoki T. and Hirono I. (2012). *Mycobacterium bovis* BCG vaccine induces non-specific immune responses in Japanese flounder against *Nocardia seriolae*. *Fish and Shellfish Immunology*, 33, pp. 243-250.
- Lee D.C., Cho M.Y. and Park S.I. (2007). A review of nocardial infection in fishes. *Journal of Fish Pathology*, 20, pp. 1-12.
- Matsumoto M., Araki K., Hayashi K., Takeuchi Y., Shiozaki K., Suetake H. and Yamamoto A. (2017). Adjuvant effect of recombinant interleukin-12 in the Nocardiosis formalin-killed vaccine of the amberjack *Seriola dumerili*. *Fish and Shellfish Immunology*. <https://doi.org/10.1016/j.fsi.2017.06.025>

- Nayak S.K., Shibasaki Y. and Nakanishi T. (2014). Immune responses to live and inactivated *Nocardia seriolae* and protective effect of recombinant interferon gamma (rIFN  $\gamma$ ) against nocardiosis in gibel carp, *Carassius auratus langsdorfii*. *Fish and Shellfish Immunology*, 39, pp. 354-364.
- Peng C., Xie J., Jin S., Zhao Q., Chen Y. and Wang G. (2013). Effects of Whole Peptidoglycan from *Nocardia seriolae* on Non-Specific Immunity of *Channa argus*. *Chinese Journal of Animal Nutrition*, 9, pp. 13-16.
- Wang P.C., Chen S.D., Tsai M.A., Weng Y.J., Ch, S.Y., Chern R.S. and Chen S.C. (2009). *Nocardia seriolae* infection in the three striped tiger fish, *Tetraodon lineatus* (Forsskal). *Journal of Fish Diseases*, 32, pp. 301-310.
- Wang G.L., Xu Y.L., Jin S., Zhu J.L. and Yuan S.P. (2007). Nocardiosis in snakehead, *Ophiocephalus argus cantor*. *Aquaculture*, 271, pp. 54-60.
- Wang P.C., Tsai M.A., Liang Y.C., Chan Y. and Chen S.C. (2014) *Nocardia seriolae*, a causative agent of systematic granuloma in spotted butterflyfish, *Scatophagus argus*, Linn. *African Journal of Microbiology Research*, 8, pp. 3441-3452.
- Xie J., Peng C.Y., Jin S., Zhao Q.S., Chen Y.E., Wang X.B. and Wang G.L. (2013). Effects of inactivated *Nocardia seriolae* on the nonspecific immune indexes of *Channa argus*. *Progress in Fishery Sciences*, 4, pp. 17-23.
-