

## Case Report

### The report of *Mycobacterium avium subsp. paratuberculosis* in a wild goat (*Capra aegagrus*) in Iran

Mohammadreza Ghorani<sup>1\*</sup>, Fahime Eslami<sup>2</sup>, Sina Soleimani<sup>3</sup>, Hossein Razi<sup>2</sup>,  
Farbod Khakpour<sup>4</sup>

- 1- Department of Pathobiology, Faculty of Veterinary Medicine, University of Tabriz, Tabriz, Iran
- 2- Department of Environment, Chaharmahal and Bakhtiari Provincial Office, Shahrekord, Iran
- 3- Razi Vaccine & Serum Research Institute, Agricultural Research, Education and Extension Organization (AREEO), Karaj, Iran
- 4- Department of Clinical Sciences, Faculty of Veterinary Medicine, Islamic Azad University-Shahrekord Branch, Shahrekord, Iran

\*Corresponding author: [mo\\_gh66@yahoo.com](mailto:mo_gh66@yahoo.com)

(Received 9 May 2023, Accepted 10 June 2023)

#### Abstract

Wild and domestic ruminants become infected with *Mycobacterium avium subsp. paratuberculosis* (MAP) leads to chronic enteritis, known as Johne's disease (JD). An eight-year-old male wild goat (*Capra aegagrus*) that lived in the wildlife breeding center in Chaharmahal and Bakhtiari province with symptoms of prolonged diarrhea that did not respond to antibiotic treatment was referred to a veterinary center. After a while, the animal died. JD was diagnosed after laboratory diagnosis (by acid-fast staining). The present study reported the incidence of JD in a wild goat in Iran for the first time. The economic losses and animal health should be considered. Since 2020, the wild goat (*Capra aegagrus*) has been classified in the category Near Threatened (NT) near treated on the list (International Union for Conservation of Nature) IUCN. Therefore, protecting the health of these species is essential. The importance of carrier animals and reservoirs in wildlife should be given special attention.

**Keywords:** *Mycobacterium avium subsp. paratuberculosis*, wild goat, Johne's disease, Iran

#### Introduction

*Mycobacterium avium subsp. paratuberculosis* (MAP) is a rod-shaped, small, aerobic, acid-fast, and intracellular bacterium of the *Mycobacterium avium* complex (Thorel et al., 1990) that is the causative agent of Johne's disease (JD), which is relatively resistant to harsh environments. MAP is a small bacilli bacterium that causes chronic disease of the intestine, cecum, and mesenteric

lymph nodes (Ayele et al., 2001). In a wide variety of free and captive artiodactyls, clinical paratuberculosis has been observed (Weber et al., 1994; Roller et al., 2020). However, non-ruminant MAP infections, such as odd-toothed hawks, rodents, lagomorphs, macropods, carnivores, birds, and inhuman primates, have also been reported (Manning, 2011; Chittick et al., 2001). Animals are significantly susceptible to infection at an early age

(Timms et al., 2011). JD exists in animals in two forms. In the multibacillary or lepromatous form, the cytoplasm of macrophages is stuffed with bacilli; there is chronically diffused granulomatous enteritis (Debroy et al., 2010). These forms can only be distinguished histopathologically. A mention is useful if pathogens' intermittent or permanent excretion is also discussed (Catton, 2002). Only adult animals older than two years are usually shown to have clinical signs. Descriptions of paratuberculosis in wild species are usually incomplete and include sporadic case reports. The infection is progressive, chronic, and resistant to treatment. The clinical disease does not develop in most infected animals, but the bacteria may be excreted. Clinically, sick animals lose weight and, in some species, develop diarrhea and may die. During this disease, MAP is excreted in feces and milk, and bacteria are transmitted through blood and lymph vessels from infected animals to other internal organs. The infection spreads to both the male and female genitals. Although MAP is not considered a pathogen in humans, discussions are ongoing on the possibility of this mycobacterium playing an important role in public health (Ayele et al., 2001).

An extended granulomatous and enteritis resistant to treatment with or without diarrhea, that leads to gradual weight loss despite ineffective food absorption, is known as classical clinical paratuberculosis (Harris and Barletta, 2001). Severe diarrhea and edema of the intermandibular are common in the late stages of cattle. Clinical signs are limited to chronic weight loss, disordered appearance, worsening of the condition, and lethargy in sheep and goats. Softer feces or diarrhea are rare and may only appear in the final stages (Stehman, 1996). The clinical signs of the disease are primarily undetectable, but when the clinical signs become apparent, the animal quickly becomes sicker and may die from the disease (Roller et al., 2020).

Useful diagnostic clues are provided by the disease course, failure to respond to treatment, and positive acid-fast lesions at necropsy are seen as clinical signs in individual animals (Roller et al., 2020).

In the case of periodic vaccination, the risks of transmission, the clinical incidence of the disease, and the rate of bacterial excretion are reduced. Vaccinated animals and tuberculosis surveillance programs interfere with serologic testing for MAP due to nonspecific responses to tuberculin skin tests, and implementation is limited (Bastida and Juste, 2011). Its proper control can be easily achieved by vaccination (Juste and Perez, 2011). Also, for infection control, accurate diagnosis of infected subclinical animals is necessary. The purpose of the study was to report the occurrences of JD in a wild goat in Iran.

## Materials and methods

### *Case history*

Wild goat (*Capra aegagrus*) is a species of wild goat that lives in the bush, forests, and rocky areas from Turkey to Pakistan. In October 2021, A wild goat (male, eight years old, weighing approximately 70 kg) lived in the wildlife breeding center in Chaharmahal and Bakhtiari province (south-west of Iran) (Figure 1) with symptoms of prolonged diarrhea that did not respond to antibiotic treatment. A poor body condition was found in the clinical examination. The wild goat was sent to a veterinary center. The goat died shortly after being transported to the veterinary center.

### *Sample collection*

Feces samples were taken fresh from the animal and were quickly sent to the microbiology laboratory with dry ice.

### *Microbiological investigation*

Ziehl-Nelsen-stained feces and intestinal mucosa smears were studied microscopically. Clusters of organisms of small acid-fast bacilli were found (Figure 2a). Smear for coccidia was also done.

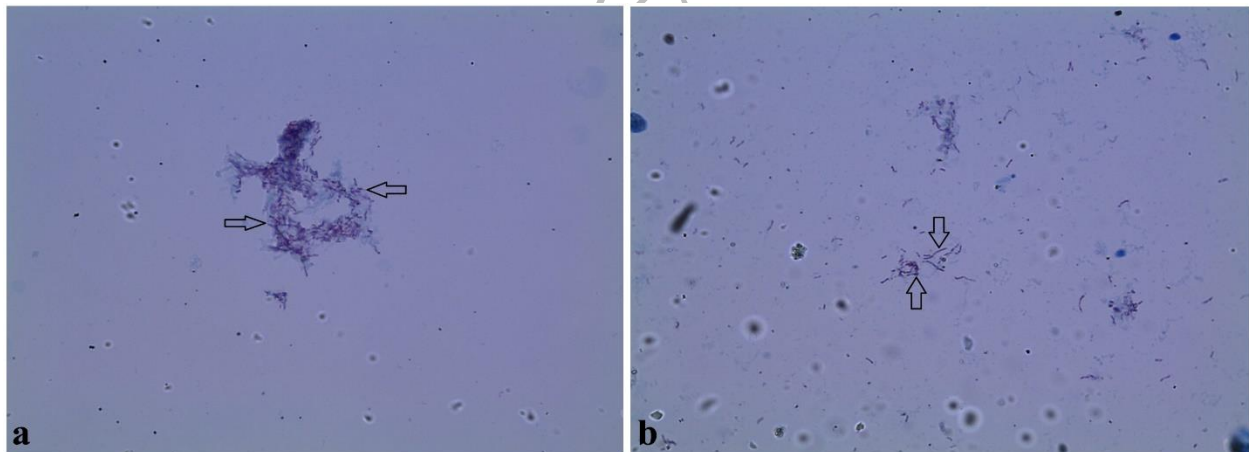


**Fig. 1.** The wild goat (*Capra aegagrus*) in the wildlife breeding center (Chaharmahal and Bakhtiari province, Iran).

### Results

For some parts of the small intestine, particularly in the distal ileum, apparent gross pathology had been observed during postmortem examination.

The acid-fast rod-shaped bacteria were detected by acid-fast staining (Figure 2b). No coccidia was found in the direct fecal smear.



**Fig. 2. a:** Clusters of organisms of small acid-fast bacilli under the light microscope ( $\times 100$  magnification). **b:** The acid-fast rod-shaped bacteria under the light microscope ( $\times 40$  magnification).

### Discussion

There is little information on the presence of MAP in different animal species in Iran. In this study, the presence of MAP was detected in a wild goat through necropsy and microscopic examinations. The tentative diagnosis was JD made based on

clinical signs, supported later by the postmortem examinations. Although MAP species is not recognized as a zoonotic disease (Whiley et al., 2012), the possibility of transmission of a common disease between humans and animals should not be ignored. Another significance of this report is that

since 2020 the wild goat (*Capra aegagrus*) has been classified in the category NT near treated on the IUCN list. Therefore, protecting the health of these species is essential.

Because the information on JD in domestic animals is limited, therefore, it is not a priority disease to control in Iran, and the ongoing spread of JD among and within goat herds must be expected. Predictably, this will be the topic for future examinations. Few previous studies have reported the presence of MAP in wild ruminants. MAP occurrence in goats, sheep, cattle, buffaloes, and deer showed the ability to infect many animal species in the country. In Iran, Nassiri et al., were identified 44% of fecal samples (from 243 specimens) and 18% of raw milk samples (from 56 specimens) of suspected cattle from some farms of Mashhad as infected with MAP (Nassiri et al., 2012). In another study, the MAP was detected in 15.1% of 212 fecal samples taken from four cattle farms in Kerman province, southeast of Iran (Soltani, 2018).

Clinical cases with characteristic lesions on domestic dwarf goats of Western Africa have been mentioned in the disease reports from Germany's zoos (Seffner, 1964). In a zoo in Missouri (USA), slow weight loss, thickening of animal hair, and diarrhea without odor were observed in Barbary sheep (*Ammotragus lervia*), and mouflon (*Ovis orientalis*) in adjacent areas with rapid disease progression and early death (Boever, 1976). After confirmation of fecal culture, necropsy, and histopathologic evaluation, a similar control regimen was administered in a top of Jimela (*Damaliscus lunatus jimela*), a subspecies of African antelope species in the USA, California (Steinberg, 1988). Dukes et al.'s report on zoos' problems with MAP described the spread of MAP in a herd of saiga antelopes (*Saiga tatarica*; Central Asian plains antelope) and their infection with mycobacterial infections in two zoos in Canada (Manitoba), has been explained (Dukes et al., 1992). The risk of interspecific transmission between animals that share a home has also been reported from a zoo in Turkey. In this report, the goats infected subclinically were identified by

complement fixation and ELISA (Cihan et al., 2006). A positive saiga antelope was reported by Orinbayev et al. In the Volga-Ural region of Kazakhstan, blood samples were collected from 286 free animals; the results showed that paratuberculosis in this species is also present in the natural population (Orynbayev et al., 2016). MAP DNA has been detected in environmental samples as well as feces of snow goats (*Oteroreamnos americanus*) and pygmy goats at another zoo in Germany (Godin, 2017). In the study by Pourmahdi Borujeni et al., the seroprevalence of MAP in goats, sheep, and cattle in southwest Iran was compared. They announced no significant relationship between animal species and MAP infection (Pourmahdi Borujeni et al., 2021).

Establishing an undeniable link and the risk of transmitting MAP from animals to humans should be considered an essential preventive measure. Therefore, developing vaccines and diagnostic systems to control MAP infection in the country's livestock population is essential.

#### **Conclusion**

Due to the risk of transmission of MAP from animals to humans, important preventive measures should be considered. Identifying the transmission of this pathogen from animals to humans allows for better evaluation of safety measures. These measures help to improve the level of public health. Therefore, developing vaccines and diagnostics systems to control MAP infection in the country's animal population is essential.

#### **Acknowledgement**

The authors thank the Chaharmahal and Bakhtiari Provincial Office of the Department of Environment.

#### **Conflict of Interests**

The authors declare that there is no conflict of interest.

#### **Ethical approval**

Not applicable.

## References

- Ayele W. Y., Machackova M. & Pavlik I. The transmission and impact of paratuberculosis infection in domestic and wild ruminants. *Veterinarni Medicina*, 2001, 46(7-8), 205-224. doi: 10.17221/7878-VETMED
- Bastida F. & Juste R. A. Paratuberculosis control: a review with a focus on vaccination. *Journal of Immune Based Therapies and Vaccines*, 2011, 9(1), 1-17. doi: 10.1186/1476-8518-9-8
- Boever W. J. John's disease in aoudads and mouflon. *The Journal of Zoo Animal Medicine*, 1976, 7(1), 19-23. doi: 10.2307/20094344
- Catton B. A. Paucibacillary paratuberculosis in a goat. *The Canadian Veterinary Journal*, 2002, 43(10), 787. URL: Paucibacillary paratuberculosis in a goat - PMC (nih.gov).
- Chittick E., Horne W., Wolfe B., Sladky K. & Loomis M. Cardiopulmonary assessment of medetomidine, ketamine, and butorphanol anesthesia in captive Thomson's gazelles (*Gazella thomsoni*). *Journal of Zoo and Wildlife Medicine*, 2001, 32(2), 168-175. doi: 10.1638/10427260
- Cihan H., Aytug N., Ozyigit M. & Akcay E. Paratuberculosis in deer and small ruminants in a zoo in Turkey. *Proceeding European Association Zoo and Wildlife Veterinarians*, 2006, 145-149.
- Debroy B., Tripathi B. & Verma D. Pathology of paratuberculosis in sheep as confirmed by ISMav2 gene real-time polymerase chain reaction. *Indian Journal of Veterinary Pathology*, 2010, 34(1), 17-22.
- Dukes T. W., Glover G. J., Brooks B. W., Duncan J. R. & Swendrowski M. Paratuberculosis in saiga antelope (*Saiga tatarica*) and experimental transmission to domestic sheep. *Journal of Wildlife Diseases*, 1992, 28(2), 161-170. doi: 10.7589/0090-3558-28.2.161
- Godin M G. C., Fell S, Straubinger RK, editors. *Vergleich zweier Methoden zur Detektion von Mycobacterium avium subsp. paratuberculosis DNA in Kot-und Umweltproben*, 2017, 37 Arbeitstagung—Verband der Zootierärzte. VZT: Innsbruck.
- Harris N. B. & Barletta R. G. Mycobacterium avium subsp. paratuberculosis in veterinary medicine. *Clinical Microbiology Reviews*, 2001, 14(3), 489-512. doi: 10.1128/CMR.14.3.489-512.2001
- Juste R. A. & Perez V. Control of paratuberculosis in sheep and goats. *Veterinary Clinics: Food Animal Practice*, 2011, 27(1), 127-138. doi: 10.1016/j.cvfa.2010.10.020
- Manning E. J. Paratuberculosis in captive and free-ranging wildlife. *Veterinary Clinics: Food Animal Practice*, 2011, 27(3), 621-630. doi: 10.1016/j.cvfa.2011.07.008
- Nassiri M., Jahandar M. H., Soltani M., Mahdavi M. & Doosti M. Identification and strain determination of *M. paratuberculosis* (MAP) by PCR and REA methods based on IS900 and IS1311 insertion segments. *Agricultural Biotechnology Journal*, 2012, 4(1), 83-96. doi: 10.22103/JAB.2012.469
- Orynbayev M. B., Beauvais W., Sansyzbay A. R., Rystaeva R. A., Sultankulova K. T., Kerimbaev A. A., Kospanova M. N. & Kock R. A. Seroprevalence of infectious diseases in saiga antelope (*Saiga tatarica*) in Kazakhstan 2012–2014. *Preventive Veterinary Medicine*, 2016, 127100-104. doi: 10.1016/j.prevetmed.2016.03.016
- Pourmahdi Borujeni M., Haji Hajikolaei M. R., Ghorbanpoor M., Elhaei Sahar H., Bagheri S. & Roveyshedzadeh S. Comparison of Mycobacterium avium subsp. paratuberculosis infection in cattle, sheep and goats in the Khuzestan Province of Iran: Results of a preliminary survey. *Veterinary Medicine and Science*, 2021, 7(5), 1970-1979. doi: 10.1002/vms3.559
- Roller M., Hansen S., Knauf-Witzens T., Oelemann W. M., Czerny C.-P., Abd El Wahed A. & Goethe R. Mycobacterium avium subspecies paratuberculosis infection in Zoo animals: A review of susceptibility and disease process. *Frontiers in Veterinary Science*, 2020, 7572724. doi: 10.3389/fvets.2020.572724
- Seffner W. Paratuberkulose (John'sche Krankheit) bei Afrikanischen Zwergziegen. *Erkrankungen der Zootiere: Verhandlungsbericht des VI*

- Internationalen Symposiums über die Erkrankungen der Zoo-und Wildtiere. Vienna, 1964.
- Soltani M. Detection of *Mycobacterium avium* subsp. *paratuberculosis* in Kerman Province's Dairy Cows using Microbial Culture, PCR and Nested PCR Methods. *Iranian Journal of Animal Science Research*, 2018, 10(2), 263-273. doi: 10.22067/IJASR.V10I2.65920
- Stehman S. M. Paratuberculosis in small ruminants, deer, and South American camelids. *Veterinary Clinics of North America: Food Animal Practice*, 1996, 12(2), 441-455. doi: 10.1016/s0749-0720(15)30416-3
- Steinberg H. Johne's disease (*Mycobacterium paratuberculosis*) in a *Jimela topi* (*Damaliscus lunatus jimela*). *The Journal of Zoo Animal Medicine*, 1988, 33-41. doi: 10.2307/20094850
- Thorel M.-F., Krichevsky M. & Lévy-Frébault V. V. Numerical taxonomy of mycobactin-dependent mycobacteria, emended description of *Mycobacterium avium*, and description of *Mycobacterium avium* subsp. *avium* subsp. nov., *Mycobacterium avium* subsp. *paratuberculosis* subsp. nov., and *Mycobacterium avium* subsp. *silvaticum* subsp. nov. *International Journal of Systematic and Evolutionary Microbiology*, 1990, 40(3), 254-260. doi: 10.1099/00207713-40-3-254
- Timms V. J., Gehringer M. M., Mitchell H. M., Daskalopoulos G. & Neilan B. A. How accurately can we detect *Mycobacterium avium* subsp. *paratuberculosis* infection? *Journal of Microbiological Methods*, 2011, 85(1), 1-8. doi: 10.1016/j.mimet.2011.01.026
- Weber R., Bryan R. T., Schwartz D. A. & Owen R. L. Human microsporidial infections. *Clinical Microbiology Reviews*, 1994, 7(4), 426-461. doi: 10.1128/cmr.7.4.426
- Whiley H., Keegan A., Giglio S. & Bentham R. *Mycobacterium avium* complex—the role of potable water in disease transmission. *Journal of Applied Microbiology*, 2012, 113(2), 223-232. doi: 10.1111/j.1365-2672.2012.05298.x