



Case Report

Disseminated pulmonary Aspergillosis in a quail flock in Iran

Ali Reza Khosravi^{1*}, Saeed Mostofi²

- 1- Mycology Research Center, Faculty of Veterinary Medicine, University of Tehran, Tehran, Iran
- 2- Veterinary Organization, Tabriz, Iran

* **Corresponding Author:** khosravi@ut.ac.ir

(Received 12 December 2021, Accepted 25 December 2021)

Summary

Aspergillosis is an important infectious fungal disease; caused the genus of *Aspergillus* that affects humans, mammals, and mainly wild or domestic birds. The following case report describes a clinical case of aspergillosis in a quail flock. A thousand flocks breeding quail originated from a hatchery located in Iran, in late spring, from the age of one week, have been encountered with breathing difficulties. The daily mortality of infected chicks was 20-30 chicks (total of 50%). The most prevalent clinical signs were respiratory symptoms such as dyspnea, open beak breathing, and increased respiration. Other clinical signs included depression, anorexia, decreasing weight, and in some stance cyanosis. The large number of white caseous nodules with an average diameter of 1-3 μm , often in the lungs and also in the liver, mesenteric intestine vessels, muscles of the chest, and heart were observed. Lungs, beak cavity, pharynx, and air sacs frequently consisted of the caseous nodules. The large numbers of germinating conidia centrally and hyphae extending peripherally through the layer of macrophages were found on the granulomas stained by Gomori's methenamine silver. In some other tissue samples, conidiophores of *A. fumigatus*, and conidial heads were formed. Mycological examination of the postmortem samples demonstrated *A. fumigatus*. Poor husbandry, ventilation, and sanitation were common conditions that predispose quails to aspergillosis in the present report.

Keywords: Fungal infection, Aspergillosis, Lung, Quail.

Introduction

Aspergillosis is an important infectious fungal disease; caused the genus of *Aspergillus* that affects humans, mammals, and mainly wild or domestic birds (Olias et al., 2010; Tell, 2005). Aspergillosis was one of the first diseases described for wild birds; it was noted in a scaup duck in 1813 and a European jay in 1815. Aspergillosis is a common infection in turkey poults, has been presented previously (Lignieres

and Petit, 1898; Kunkle and Sacco, 1998; Akan et al, 2002). Generally, aspergillosis is a respiratory infection, but the brain and the eye can affect. Two forms of the disease are commonly reported in poultry: Acute and chronic aspergillosis. Very young birds affected by severe outbreaks of acute aspergillosis. Then exhibit mortality is observed in birds a few days old. Dyspnea, panting, and inappetence are frequent clinical signs of infected birds. Tissue lesions initially are found in the air sacs and the lungs, but disseminated rapidly and

account for other clinical signs like diarrhea and encephalitis. Chronic aspergillosis occurs in adult turkeys. Birds generally survive, but because of the low efficiency resulting in significant financial disadvantage (Fuller et al., 2003). The most prevalent pathogenic species is *Aspergillus fumigatus*. Other potentially pathogenic species are *A. flavus*, *A. niger*, *A. nidulans*, and *A. terreus* (Sanchez and Murray, 2005). The respiratory disease is common in companion and captivity birds, especially chicks and turkeys and rare among free-living birds (Sanchez and Murray, 2005; Famenia et al., 2007; Chege, 2013). The disease is during the first week or so of life and usually arises from contaminated litter. If the infection is acquired in the hatchery, pneumonia can develop in two days of age birds. Sometimes, lesions are restricted to the bronchi and are observed after cutting through. Usually, the military lesions were seen in the lung and occasionally in the trachea, so they consist of rapidly developing granulomas and caseous plaques in the air sacs. Aspergillosis was previously reported from different birds such as penguins (Bechert et al., 2010), raptors (Forbes, 1991), vulture (Chege, 2013), and waterfowl (Bowes, 1990).

The epidemiology of aspergillosis is unknown in Iran. There is little information concerning the incidence of avian aspergillosis in Iran. Khosravi *et al.* reported an outbreak of severe disseminated aspergillosis in a flock of ostrich (Khosravi *et al.*, 2008). Kheirandish *et al.* (2013) investigated clinical, pathological, and mycological findings in canaries with aspergillosis. Here, we described clinical cases of aspergillosis in a quail flock. Although aspergillosis has been studied extensively in captive or free-living birds, the reports in quails and also from Iran are limited.

Case Report

Clinical history

A thousand flocks breeding quail originated from a hatchery located around the city of Karaj, Iran, in late spring, from the age of one week, have been encountered with breathing difficulties. The quails could lie in two groups; among the quail chicks, 40% were 12 days old, and 60% were 22 days old. In both age groups, white and gray quails were reared. The quails were reared in the poultry house, consisted of two parts, which was wrapped with a plastic pan. In each part, one age group was kept. The environment of keeping had poor ventilation and poor sanitation leads to increased concentration of spores in the environment that predispose a bird to aspergillosis. The average salon temperature was 30°C and humidity was 70%. A total of thousand flocks breeding quails, 400 quail chicks showed respiratory symptoms and problems. The mortality rate was more in 12 days old quails than 22 days old as over fifty percent of involved chicks were belong to 12 days quails. On the other hand, the disease was less in white chicks than grays. The daily mortality rate of infected chicks was 20-30 chicks (total of 50%). The disease was progressive in the flock. The most prevalent clinical signs were respiratory symptoms like dyspnea, open beak breathing, and increased respiration. Other clinical signs included depression, anorexia, decreasing weight, and in some stances cyanosis. Also, some infected chicks had white exudates and discharged from the anus or watery diarrhea. Alopecia with an average diameter of 2 cm in the lumbar area of most of the birds in the farm was observed. Birds died suddenly with a respiratory system involving signs. For Mycological and histological examination, a necropsy was performed in a septic condition. Swabs from trachea and pharynx and air sac samples were collected from new dead quails. Swabs and tissue (after preparation) samples were inoculated on SDA and Brain Heart Infusion broth with chloramphenicol (0.05 mg/ml) and incubated at 25°C and 37°C under aerobic conditions. Also, samples from the litter and feed were cultured on SDA. The tissue samples after fixation in formalin

and processing were stained by hematoxylin and eosin (HE) and periodic acid-Schiff (PAS) methods. Eventually, the tissue sections were evaluated by a light microscope.

Necropsy and Histopathology

The large number of white caseous nodules with an average diameter of 1-3 μm , often in the lungs and also in the liver, mesenteric intestine vessels, muscles of the chest, and heart were observed. Lungs, beak cavity, pharynx, and air sacs frequently consisted of the caseous nodules. Histopathological findings included inflammatory response, necrotic fungal dichotomously hyphae and fibrous tissue. Air sac membranes were thickened up by massive infiltration of leukocytes such as heterophils and multinucleated giant cells. A zone of heterophils, macrophages, and tissue debris surrounded the foci. The larger foci were encapsulated by fibrous tissue and infiltration of lymphocytes, macrophages, and occasionally multinuclear cells. Granulomas had centers consisted of necrotic cellular debris and heterophils with a peripheral palisade of epithelioid macrophages and lymphocytes (Figure 1). The granulomatous tissue expanded and compressed the adjacent alveoli. The large numbers of germinating conidia centrally and hyphae extending peripherally through the layer of macrophages were observed on the granulomas, which stained by GMS. In some other tissue samples, conidiophores of *A. fumigatus*, and conidial heads were formed (Figure1-3).

Mycology

The mycological examination demonstrated *A. fumigatus* in post mortem samples. The fungal culture revealed the growth of *A. fumigatus* in all birds. However, along with the intensive growth of *A. fumigatus*, some saprophytic fungi such as other *Aspergillus* and *Penicillium* species were grown in fungal cultures.

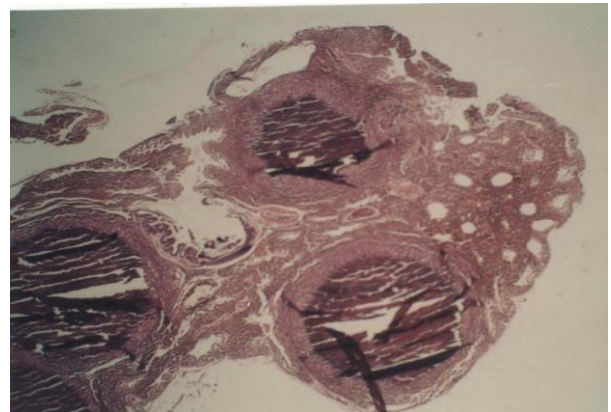


Fig. 1. Lung, quail, and acute aspergillosis. There are two granulomas with the caseous center and peripheral granulomatous reaction (H&E, 40 \times).

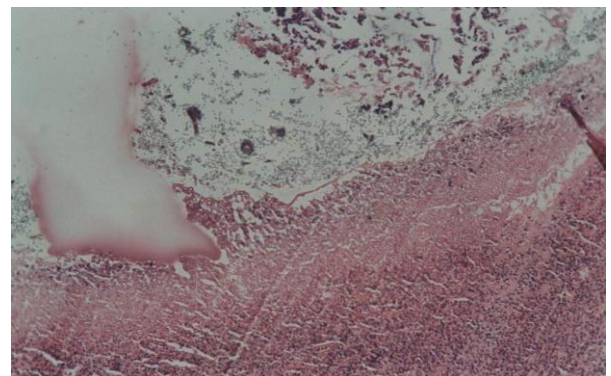


Fig. 2. Abdominal air sac, quail, and acute aspergillosis. A thickened abdominal air sac associated with inflammatory cells and characteristic conidial head (*Aspergillus fumigatus*) (H&E, 40 \times).

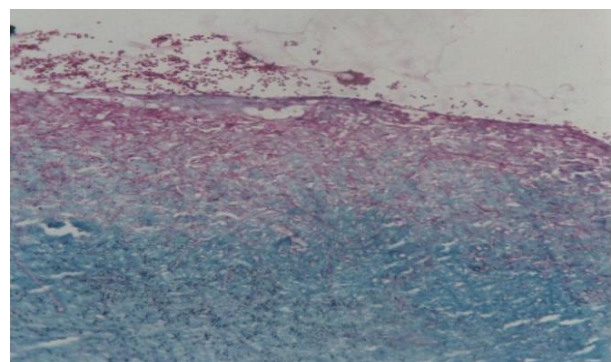


Fig. 3. Abdominal air sac, quail, and acute aspergillosis. A thickened abdominal air sac associated is infiltrated by fungal hyphae and characteristic conidiophores (*Aspergillus fumigatus*) (H&E, 40 \times).

Discussion

Aspergillosis is well known as a common fungal infection cause of morbidity and mortality in all avian species with various age range and environments (Beernaert et al., 2010). Predisposing factors include species predilection, environmental conditions such as limited air exchange, exposure to aerosolized toxins leading to mucosal irritation, and inappropriate temperature and humidity, immunosuppression, physical exertion, and corticosteroids therapy. The quails need about 45 to 60 % humidity and 37°C temperature; in the present report, the humidity and temperature of the salon were 70% and 30°C respectively, so that they may affect the development of the disease. The route of inoculation is breathing, and the lower respiratory tract is the location where *Aspergillus* species tend to colonize initially. Approximately 95% of aspergillosis cases are due to *A. fumigatus* and *A. flavus* is the second most frequent organism related with avian infections. In the present report, *A. fumigatus* was the most isolated organisms from clinical samples. Clinical signs are usually nonspecific or can be related to compromise of the respiratory system, rhinitis, change in vocalization, and dyspnea. Also, we found the most prevalent clinical signs were respiratory symptoms in the quails. The clinical forms of the infection that have been demonstrated in birds comprise aspergilloma, multifocal lesions, and disseminated aspergillosis. Regarding the target tissues are lungs and air sacs, the macroscopic pathologic lesions include plaques or caseous nodules, and necrotic granulomas can be confirmed on histopathology (Figure 2). The susceptibility of quails to aspergillus related to innate and acquired immunity against fungi. Conidia of *A. fumigatus* disseminated *Hematogenously* and white caseous nodules in tissues such as liver and heart were observed isolated *A. fumigatus* from the blood of turkeys immediately after a 15-minute aerosol exposure of conidia (Arne et al., 2011). At this time, lung

macrophages contained numerous ingested conidia. This may be the route of dissemination resulting in other tissue lesions. Most cases of avian aspergillosis have been related to changes in litter management. The subsequent treatment of the bed with a fungistatic compound decreased mortality. In two broiler houses, the displacement of rice-hull beddings by *A. fumigatus* contaminated sunflower shell was related to aspergillosis. Removal of mouldy litter led to health improvement (Zafra et al., 2008). The sporadic use of fresh sugarcane bagasse was associated with up to 90% mortality in young chickens. The very high moisture of the fresh material is highly favorable for *A. fumigatus* growth and sporulation. No clinical case occurred after the reintroduction of stored bagasse as litter (Arne et al., 2011).

Conclusion

Taken to gather, poor husbandry, ventilation, sanitation were common conditions that predispose quails to aspergillosis in the present report.

Acknowledgments

Not applicable

Conflict of interest statement

The authors declare no conflicts of interest.

Ethical approval

No applicable

References

- Akan M., Hazroğlu R., İlhan Z., Sareyyüpoğlu B., Tunca R. A case of aspergillosis in a broiler breeder flock. *Avian Diseases*, 2002, 46(2), 497–501.
- Arné P., Thierry S., Wang D., Deville M., Le Loc'h G., Desoutter A., Guillot J. *Aspergillus fumigatus* in Poultry. *International Journal of Microbiology*, 2011, 746356.
- Bechert U., Christensen J. M., Poppenga R., Le H., Wyatt, J. and Schmitt T. Pharmacokinetics of orally administered terbinafine in African penguins (*Spheniscus demersus*) for potential

- treatment of aspergillosis. *Journal of Zoo and Wildlife Medicine*, 2010, 41, 263-274.
- Bernaert L.A., Pasmans F., Van Waeyenberghe L., Haesebrouck F., Martel A. *Aspergillus* infections in birds: a review. *Avian Pathology*, 2010, 39(5), 325–331.
- Bowes V. A. British Columbia. An outbreak of aspergillosis in wild waterfowl. *Canadian Veterinary Journal*, 1990, 31, 303-304.
- Féménia F., Fontaine J.J., Lair-Fulleringer S., Berkova N., Huet D., Towanou N., Rakotovo F., Granet O.I., Le Loc'h G., Arné P., Guillot J. Clinical, mycological and pathological findings in turkeys experimentally infected by *Aspergillus fumigatus*. *Avian Pathology*, 2007, 36(3), 213–219.
- Forbes N. A. Aspergillosis in raptors. *Veterinary Records*, 1991, 128 (11), 263.
- Kheirandish R., Aakari N. and Salehi M. Clinical and pathological findings of concurrent poxvirus lesions and aspergillosis infection in canaries. *Asian Pacific Journal of Tropical Biomedicine*, 2013, 3, 182-185.
- Khosravi A.R., Shokri H., Ziglari T., Naeini A.R., Mousavi Z., Hashemi H. Outbreak of severe disseminated aspergillosis in a flock of ostrich (*Struthio camelus*). *Mycoses*, 2008, 51, 557-559.
- Kunkle R. A. and Sacco R. E. Susceptibility of convalescent turkeys to pulmonary aspergillosis. *Avian Disease*, 1998, 42, 787-790.
- Lignieres J. and Petit G. Péritonite aspergillaire des dindons (*Aspergillus peritonitis* of turkey toms) *Recueil de Médecine Veterinaire*, 1998, 5, 145-148.
- Olias P., Hauck R., Windhaus H., Grinten E.v.d., Gruber A.D., Hafez H.M. Articular aspergillosis of hip joints in turkeys. *Avian Disease*, 2010, 54, 1098-1101.
- Sanchez C. R. and Murray S. Z. Diagnosis and successful treatment of a presumptive case of aspergillosis in a Micronesian kingfisher (*Halcyon cinnamomina cinnamomina*). *Avian Disease*, 2005, 49, 309-312.
- Chege S., Howlett J., Al Qassimi M., Toosy A., Kinne J. and Obanda V. Opportunistic infection of *Aspergillus* and bacteria in captive Cape vultures (*Gyps coprotheres*). *Asian Pacific Journal of Tropical Biomedicine*, 2013, 3(5), 401-406.
- Lair-Fulleringer S., Guillot J., Desterke C., Seguin D., Warin S., Bezille A., Bretagne S. Differentiation between Isolates of *Aspergillus fumigatus* from Breeding Turkeys and Their Environment by Genotyping with Microsatellite Markers. *Journal of Clinical Microbiology*, 2003, 41(4), pp.1798–1800.
- Tell L. A. Aspergillosis in mammals and birds: impact on veterinary medicine. *Medical Mycology*, 2005, 43, 71-73.
- Zafra R., Perez J., Perez-Ecija R.A. Borge C., Bustamante R., Carbonero A., Tarradas C. Concurrent aspergillosis and ascites with high mortality in a farm of growing broiler chickens. *Avian Diseases*, 2008, 52(4), 711–713.