



## **Case Report**

### **A case report of *Sarcocystis* sp. isolated from a tumor-like tissue mass on the back of a 6-year-old ewe in Isfahan, Iran**

**Nasser Hajipour<sup>1\*</sup>, Mehdi Salimi<sup>2</sup>, Habib Allah Rashidzadeh<sup>2</sup>, Ata Kaboudari<sup>3</sup>**

1- Department of Pathobiology, Faculty of Veterinary Medicine, University of Tabriz, Tabriz, Iran

2- Graduated of Veterinary Medicine, Faculty of Veterinary Medicine, University of Shahrekord, Shahrekord, Iran

3- Department of Food Hygiene and Quality Control, Faculty of Veterinary Medicine, Urmia University, Urmia, Iran

\* **Corresponding author:** [n.hajipour@tabrizu.ac.ir](mailto:n.hajipour@tabrizu.ac.ir)

(Received 13 January 2021, Accepted 14 February 2021)

#### **Summary**

Sarcocystosis is a zoonotic disease in sheep caused by an intracellular parasite belongs to the phylum Apicomplexa, order Eucoccidioria, and Sarcocystidae family. In the parasite life cycle, there is a need for an intermediate host and a definite host. Some species of *Sarcocystis* can cause disease and consequently cause weight loss, anorexia, fever, anemia, muscle weakness, decreased milk production, abortion, and sometimes death in intermediate hosts such as cattle, goats, and sheep. Cysts of *Sarcocystis* spp. are found nearly always in skeletal, striated muscles, particularly in the diaphragm, heart, liver, lungs, and esophageal. A six-years-old native ewe was referred to the veterinary clinic in Najafabad, Isfahan province, Iran with major clinical signs of nasal discharge, enlarged superficial lymph nodes, anorexia, and a round tumor-like mass on the back. After tissue processing and hematoxylin and eosin staining, different sizes of *Sarcocystis* spp. (with  $3.03 \pm 0.44 \mu\text{m}$  in length) each surrounded by a thin layer of muscle fibers and contained banana-shape bradyzoites were seen in the subcutaneous muscle fibers. Hemorrhage and infiltration of inflammatory cells, mainly, neutrophils were also seen in the dermis.

**Keywords:** Sarcocystosis, Ewe, Histopathology, Case report

#### **Introduction**

Sarcocystosis, a food borne zoonotic disease, is caused by *Sarcocystis* spp. with worldwide distribution in humans, animals, and birds, and has a significant economic impact on the production of domestic animals as well as public health (Chen et al., 2011). *Sarcocystis* species have a life cycle with two hosts, herbivores as intermediate host and carnivores as definitive host. Human beings act as

a definitive host for some species and get infected by eating raw or undercooked meat (Dhaliwal and Juyal, 2016). There have been only four validated species described in sheep: the non-pathogenic macroscopic *S. gigantea* and *S. medusiformis* transmitted by felids and the pathogenic microscopic *S. tenella* and *S. arieticanis* transmitted by canids (Dubey, 2016). In general, the *Sarcocystis* spp. transmitted by canids are more

pathogenic than those transmitted by the feline. *S. tenella* can lead to acute sarcocystosis in uninfected sheep. Nonspecific infection symptoms including fever, anorexia, tachycardia, and anemia could be observed following infection. In acute sarcocystosis, the central nervous system will be involved, and it can cause encephalitis and encephalomyelitis and subsequently death in sheep (Uggla and Buxton, 1990). Neurological disorders with muscle weakness, trembling, ataxia followed by hind limb paresis or flaccid paralysis and recumbency are evident in clinical form (Radostits et al., 2007). In severe infection of esophagus muscle, esophageal dysfunction and regurgitation are expected. In some cases, cachexia, fever, anemia, in appetite, and alopecia were also reported (Titilincu et al., 2008).

Many studies about the distribution of sarcocystosis in slaughtered cattle, pigs, sheep, and horses have been carried out in different countries of Europe, North and South America, Asia,

Australia, and Africa (Dubey et al., 2015; Farhangpazhouh et al., 2020). The aim of this study was to determine the cause of a tumor-like tissue mass on the back of a 6-years-old ewe referred to Najafabad Veterinary Clinic, Isfahan, Iran.

### Case History and Clinical Findings

A six-years-old native ewe with major clinical signs, including nasal discharge, enlarged superficial lymph nodes, and anorexia, was referred to a veterinary clinic in Najafabad, Isfahan province, Iran. Also, there was a round tumor-like mass about 23.2 cm × 3.5 cm in diameter on the back area (Figure 1). The mass was alopecic, and its surface was rough. At the first step, the mass was removed, but after two weeks, it was appeared again. A sample from the tissue formed on the back of ewe was isolated and placed in 10% formalin and 37% paraffin and then was stained with hematoxylin and eosin (H&E) for histopathological examination.

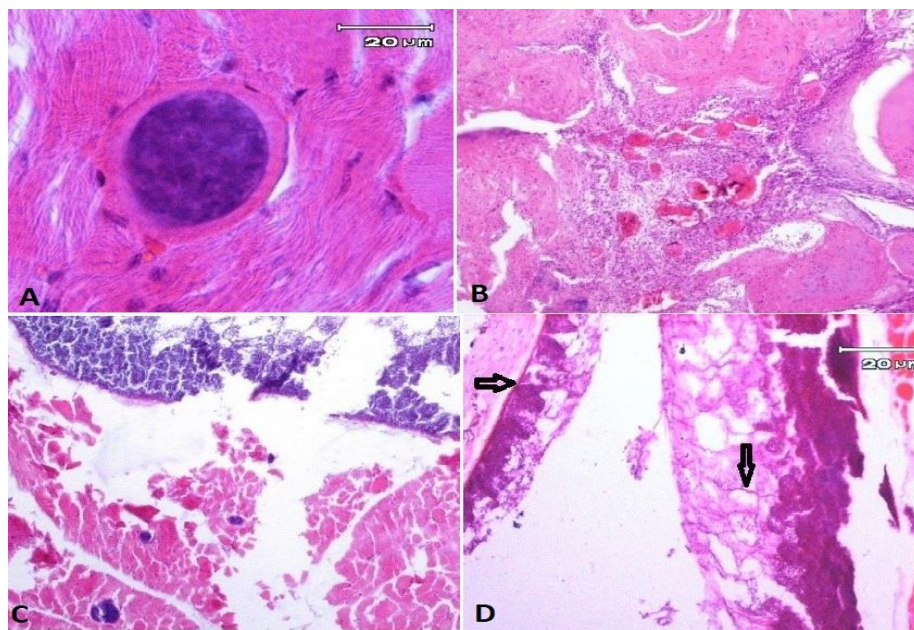


**Fig.1.** The tumor-like mass with a rough surface on the back of the affected sheep.

### Histopathological Findings

Under the light microscope, different sizes of *Sarcocystis* were seen in the subcutaneous muscle fibers (with  $3.03 \pm 0.44 \mu\text{m}$  in length), each surrounded by a thin layer of muscle fibers and contained banana-shaped bradyzoites. There was not any tissue reaction around the cysts (Figure 2). In addition to microscopic cysts, a macroscopic cyst with distinct anterior and posterior shape was

seen in the subcutaneous muscles: The cyst containing bradyzoites had a thin wall and showed internal irregular septations (Figure 2). The epidermis overlying the cyst showed acanthosis, severe hyperkeratosis, and necrosis of epidermal cells (Figure 2). Hemorrhage and infiltration of inflammatory cells, mainly, neutrophils were also seen in the dermis (Figure 2).



**Fig.2.** Tissue section isolated from the back of the sheep. A: Round shape *Sarcocystis* contained bradyzoites in the myocyte (H &E, X 100), B: Severe hyperkeratosis with hemorrhage and infiltration of inflammatory cells in the dermis (H &E, X 100), C: Mix infection of macroscopic and microscopic *Sarcocystis* in the subcutaneous muscular tissue (H &E, X 100), D: *Sarcocystis* sp. cyst. The cyst has a thin wall (left arrow). The internal irregular septations is demonstrated (right arrow) (H&E, X 40).

### Discussion

In this study, a case of *Sarcocystis* spp. infection in an ewe with clinical symptoms of severe hyperkeratosis and superficial lymph nodes enlargement was reported. The enlargement of lymph nodes can occur because of the third generation of schizogony in the lymphocytes (Landsverk et al., 1978). Previously, in an experimental study with *S. gigantea* in rats (Al-

Taei et al., 2011), hyperplasia of lymphoid tissue around bronchi have been reported. In another experimental study with *S. gigantea* in lamb, mild encephalitis, characterized by the presence of small microglial nodules scattered throughout the brain, was reported at 21-42 days post-inoculation. But, the bradyzoites have not been demonstrated in lesions.

In this case study, hyperkeratosis and sub-epidermal hemorrhages might have occurred by the second schizogony generation in the vascular endothelial cells associated with *Sarcocystis* spp. (Hillyer et al., 1991). Since the *Sarcocystis* species was not identified in the present study, the cause of respiratory symptoms observed in the ewe may be due to other infectious diseases or sarcocystosis. In support of this, Bacci et al. (2016) have reported respiratory symptoms due to *Sarcocystis tenella* in young sheep (Bacci et al., 2016).

Moreover, neurological symptoms involving recumbency, weakness, ataxia, mild hyperesthesia, and dorsiflexion of the neck due to *S. capracanis* (goat pathogen) have been reported in sheep (Formisano et al., 2013).

Veronesi et al. (2020) have described the myofibers invasion in a horse infected by *S. gigantea*, a sheep-specific species, with low virulence in the original host. The horse was referred to the clinic of a veterinary surgeon, and the data suggested that the horse had an initial history of swelling of the right forelimb with fluid on the front of the carpus and edema spreading up the forearm. Subsequently, two firm lumps were found on the left pectoral muscle adjacent to the axilla of the left forelimb. The histologic examination of biopsies of the tumor-like tissue mass revealed multifocal granulomatous eosinophilic myositis associated with intact and degenerated encysted parasites, which were consistent with *Sarcocystis* spp. Finally, after amplifying and DNA sequencing of the 18S rRNA gene obtained from formalin-fixed, paraffin-

embedded tissue blocks, *S. gigantea* was identified (Veronesi et al., 2020).

#### Acknowledgments

The authors would like to thank Dr. Iraj Karimi for preparing tissue sections and interpreting data.

#### Conflict of interest statement

There is no conflict of interest.

#### Ethical approval

Not applicable.

#### Reference

- Al-Taei A.F., Kennany E.R. & Al-Hyali N.S. Effect of lysate of *Sarcocystis gigantea* in rats. *Iraqi Journal of Veterinary Sciences*, 2011, 25(2), 81-85.
- Bacci C., Vismarra A., Passeri B., Sciarrone F., Mangia C., Genchi M., Fabbi M., Vicari N., Bruini I., Brindani F. & Kramer L. Detection of *Toxoplasma gondii* and *Sarcocystis tenella* in indigenous Cornigliese sheep in Italy using serological and molecular methods. *Small Ruminant Research*, 2016, 135, 13-16.
- Chen X., Zuo Y., Rosenthal B.M., He Y., Cui L. & Yang Z. *Sarcocystis sinensis* is an ultrastructurally distinct parasite of water buffalo that can cause foodborne illness but cannot complete its life-cycle in human beings. *Veterinary Parasitology*, 2011, 178(1-2), 35-39.
- Dhaliwal B.B.S. and Juyal P.D. 2016, *Parasitic Zoonoses*. Springer, New York, 30-31.
- Dubey J.P., Van Wilpe E., Calero-Bernal R., Verma S.K. & Fayer R. *Sarcocystis heydorni*, n. sp.(Apicomplexa: Sarcocystidae) with cattle (*Bos taurus*) and human (*Homo sapiens*) cycle. *Parasitology Research*, 2015, 114(11), 4143-4147.
- Dubey J.P. 2016, *Sarcocystosis of animals and humans*. (2nd Edn). Taylor and Francis, New York.
- Farhangpazhouh F., Yakhchali M., Farshid A. &

- Rezaei H. Prevalence and pathologic changes due to *Sarcocystis* species in naturally infected sheep in Urmia city , Iran. *Journal of Zoonotic Diseases*, 2020, 4(3), 54-60.
- Formisano P., Aldridge B., Alony Y., Beekhuis L., Davies E., Del Pozo J., Dunn K., English K., Morrison L. & Sargison N. Identification of *Sarcocystis capracanis* in cerebrospinal fluid from sheep with neurological disease. *Veterinary Parasitology*, 2013, 193(1-3), 252-255.
- Hillyer E.V, Anderson M.P., Greiner E.C., Atkinson C.T. & Frenkel J.K. An outbreak of *Sarcocystis* in a collection of psittacines. *Journal of Zoo and Wildlife Medicine*, 1991, 434-445.
- Landsverk T., Gamlem H. & Svenkerud R. A *Sarcocystis*-like protozoon in a sheep with lymphadenopathy and myocarditis. *Veterinary Pathology*, 1978, 15(2), 186–195.
- Radostits O.M., Gay C.C., Hinchcliff K.W. & Constable P.D. 2007, *Veterinary Medicine*, 10<sup>th</sup> ed. Saunders Elsevier, Philadelphia, USA, 673-748.
- Titilincu A., Mircean V., Blaga R., Bratu C.N. & Cozma V. Epidemiology and etiology in sheep sarcocystosis. *Bulletin of University of Agricultural Sciences and Veterinary Medicine Cluj-Napoca. Veterinary Medicine*, 2008, 65(2), 49-54.
- Uggla A. & Buxton D. Immune responses against *Toxoplasma* and *Sarcocystis* infections in ruminants: diagnosis and prospects for vaccination. *Revue Scientifique et Technique (International Office of Epizootics)*, 1990, 9(2), 441-462.
- Veronesi F., Di Palma S., Gabrielli S., Morganti G., Milardi G.L., Middleton B. & Lepri E. *Sarcocystis gigantea* infection associated with granulomatous eosinophilic myositis in a horse. *Journal of Veterinary Diagnostic Investigation*, 2020, 32(4), 611-615.
-