

## A case report of *Diocotophyma renale* in the peritoneal cavity of a stray dog

Parisa Shahbazi, Amir Ali Shahbazfar, Roghayeh Norouzi\*

Department of Pathobiology, Faculty of Veterinary Medicine, University of Tabriz, Tabriz, Iran

\*Corresponding author: [r.norouzi@tabrizu.ac.ir](mailto:r.norouzi@tabrizu.ac.ir)

(Received 20 July 2016, Accepted 24 September 2016)

### Summary

*Diocotophyma renale* (giant kidney worm), is an uncommon parasitic roundworm that may affect both humans and other mammals. This study reports a case of parasitism by the *Diocotophyma renale* in the peritoneal cavity with both sexes of worms in a stray dog from East Azerbaijan, Iran. A male adult stray dog was taken to the Department of Animal Pathology, Faculty of Veterinary Medicine, University of Tabriz, Tabriz, Iran. Clinical signs were suggestive of a case of peritonitis. During necropsy, two brownish-red nematodes, were found in the abdominal cavity and was identified as male and female adult *D. renale*. Adult male worm measured up to 35 cm x 6-7 mm wide, and female was up to 36 cm x 7-9 mm wide. This study reports the first confirmed case of diocotophymatosis with both sexes of worms in the dog. The parasite's aberrant location in the peritoneal cavity suggests that the dog is not a suitable host.

**Keywords:** *Diocotophyma renale*, peritoneal cavity, stray dog, East Azerbaijan, Iran.

### Introduction

The giant kidney worm, *Diocotophyma renale*, is one of the largest known parasitic nematodes (Soulsby, 1978). Its life cycle is complex and requires an aquatic oligochaete, *Lumbriculus variegatus* (Anderson, 2000), as intermediate host. Definitive hosts, which are usually many mammalian species including, dogs, mink, wolves, foxes, jackals, coyotes, skunks, ferrets, weasels, rats, raccoons, wolverines, pumas, cats, seals, pigs, horses and humans, despite the rare occurrence (Kumar et al., 1972; Samuel et al., 2008; Tokiwa et al., 2011). This nematode, known since the late 16<sup>th</sup> century and was first described from specimens found in the kidney of a dog by Goeze in 1782. It inhabits temperate regions worldwide, particularly areas with freshwater streams and lakes. The worms were found in various organs in host body

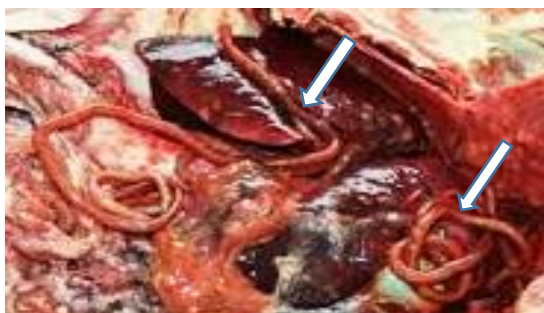such as the kidneys, scrotum, breasts, thoracic cavity, peritoneal cavity, bladder, and subcutaneous layer. However, they can also be found in ectopic locations. (Ignjatovic et al., 2003; Verocai et al., 2009; Acosta et al., 2008). Female worms can be over 100 cm long and male worms measured 35 cm, although their size may vary according to the affected species (Kumar et al., 1972). Male worms have a bell-shaped copulatory bursa that does not present rays and has one spicule (Kumar et al., 1972).

Diocotophymatosis is a zoonotic disease, but in the case of humans, locations outside the kidney are frequent (Sun et al., 1986; Urano et al., 2001). Less than 20 cases of diocotophymatosis in human have been confirmed worldwide. Human diocotophymatosis has been reported from Iran (Hanjani et al, 1968; Zolhavarieh et al.,

2016) and other parts of the world (Ignjatovic et al., 2003; Sun et al., 1986; Urano et al., 2001; Beaver et al., 1979; Beaver et al., 1984; Fernando, 1983). Although animal infection with this parasite occurs in Iran, but this report is a first case of parasitism by the *Diectophyma renale* in the peritoneal cavity with both sexes of worms in a stray dog.

### Case report

A male adult stray dog was taken to the Department of Animal Pathology, Faculty of Veterinary Medicine, University of Tabriz, Iran. During the necropsy, two brownish-red nematodes were found in the abdominal cavity. The parasites were placed in a 10% formalin solution. The worms were identified using microscopic examination as the male and female *Diectophyma renale*. The adult male worm has a bell-shaped copulatory bursa that does not present rays and has one spicule and worm measured up to 35 cm × 6-7 mm wide. Adult female worm that does not present copulatory bursa and measure up to 36 cm × 7-9 mm wide (Fig. 1, 2, 3).




**Fig 1.** Opened peritoneal cavity of stray dog showing location of two *Diectophyma renale* worms (arrows)

**Fig 2.** Adult male and female *Diectophyma renale* (35 and 36 cm long) removed from peritoneal cavity of stray dog



**Fig 3.** A bell-shaped copulatory bursa of adult male worm



### Discussion

In the evolutionary cycle of *Diectophyma renale*, the intermediate host for this giant kidney worm is an aquatic oligochaete annelid (*Lumbriculus variegatus*) that ingests eggs of the first stage containing larvae of the parasite. The primary host is infected by ingesting the infected annelid or paratenic host which can be a fish or frog (Freitas, 1980).

In most cases of *D. renale* infection in dogs the parasite is located within the right kidney and rarely seen in the urinary bladder (Soulsby, 1978; Freitas, 1980). The greater occurrence of this nematode in the right kidney compared with left side is directly related to the anatomic position of this organ to the duodenum where *D. renale* frequently leaves the gut during its migratory route (Olsen, 1977). The adult nematodes are found in the left kidney

when they perforate the stomach at the larger curvature, while the presence of encysted *D. renale* around hepatic tissue is associated with crossing of the worm at the small curvature of the stomach (Kommers et al., 1999). The predominance of both sexes of the nematode is similar in the kidney of the infected mink and other wild fish-eating carnivores and their domestic relatives (Mace, 1976). However, this report is a first case of parasitism by the *D. renale* in the peritoneal cavity with both sexes of worms, of a stray dog from Iran. The parasite's aberrant location in the abdominal cavity suggests that the dog is not a suitable host. Most cases of *D. renale* described in dogs in Brazil occurred in mongrels, stray dogs or in the housed-kept dogs that had restricted access to the street (Leite et al., 2005).

Most cases of canine diocytophymosis are asymptomatic (Soulsby, 1978) or the clinical signs are not suggestive of renal disease. Death in canine diocytophymosis has been associated with urine retention and uremia (Soulsby, 1978) due to chronic renal insufficiency. The urine retention and uremia in association with hemorrhagic shock may possibly be the underlying causes of sudden death in the cases described.

Human infections by *D. renale* have been very rare and seem to have occurred accidentally. No more than 20 confirmed human cases have been reported worldwide in which worms were found in various organs of the body, e.g. the kidneys and peritoneal cavity. Diocytophymatid larvae were found in subcutaneous nodules in 4 out of 20 human cases. However, according to Le Bailly et al. (2003), the parasite has been found in archaeological material dating from 3384 to 3370 BC.

In the context of this zoonosis, several factors pose a risk to the health of the local inhabitants: high prevalence of infected canines, high level of surface contamination, and use of the river as a means of transport, recreation and fishing for food (fish, frogs and eels) (Burgos et al., 2014). The continuation of the life cycle of *D. renale* is directly related to water temperature and egg embryonation (Soulsby, 1978).

## References

- Acosta W.G., Burgos L. and Radman N.E. (2008). Evaluación de la presencia renal y extrarenal de *Diocytophyma renale* por ultrasonografía, en caninos y humanos de un área endémica. *Revista de enfermedades infecciosas emergentes*, 3: pp. 40.
- Anderson R.C. (2000). Nematode Parasites of Vertebrates: Their Development and Transmission, 2nd ed. CAB Publishing, London, England, 672.
- Beaver P.C. and Khamboonruang C. (1984). Diocytophyma-like larval nematode in a subcutaneous nodule from man in Northern Thailand. *American Journal of Tropical Medicine and Hygiene*, 33: pp. 1032-1034.
- Beaver P.C. and Theis J.H. (1979). Diocytophymatid larval nematode in a subcutaneous nodule from man in California. *American Journal of Tropical Medicine and Hygiene*, 28: pp. 206-212.
- Burgos L., Acosta R.M., Fonrouge R.M., Archelli S.M., Gamboa M.I., Linzitto O.R., Linzitto J.P., Osen

- B.A. and Radman N.E. (2014). Prevalence of a zoonotic parasite, *Diectophyma renale* (Goeze, 1782), among male canines in a wild riverside area of La Palata river, province of Buenos Aires, republic of Argentina. *Revista de Patologia Tropical Journal*, 43 (4): pp. 420-426.
- Fernando S.S. (1983). The giant kidney worm (*Diectophyma renale*) infection in man in Australia. *American Journal of Surgical Pathology*, 7: pp. 281-284.
- Freitas M.G. (1980). Helminthologia Veterinária, fourth ed. *Grafica Rabelo, Belo Horizonte*, pp. 267–270.
- Hanjani A.A., Sadighian A., Nikakhtar B. and Arfaa F. (1968). The first report of human infection with *diectophyma renale* in Iran. *Transactions of the Royal Society of Tropical Medicine and Hygiene*. 62: pp. 647-648.
- Ignjatovic I., Stojkovic I., Kutlesic C. and Tasic S. (2003). Infestation of the human kidney with *Diectophyma renale*. *Urologia Internationalis*, 70: pp. 70-73.
- Kommers D.G., Ilha M.R.S. and Barros C.S.L. (1999). *Diectofimose em cães: 16 casos. Ciência Rural*, 29: 517–522.
- Kumar V., Vercruysse J. and Vandesteene R. (1972). Studies on two cases of *Diectophyma renale* (Goeze, 1782) infection in *Chrysocyon brachyurus* (Illiger). *Acta zoologica et pathologica Antverpiensia Journal*, 56: pp. 83-98.
- Le Bailly M, Leuzinger U. and Bouchet F. (2003). *Diectophymidae* eggs in coprolite from Neolithic site of Arbon-Bleiche 3 (Switzerland). *Journal of Parasitology*, 89: pp. 1073-1076.
- Leite L.C., Círio S.M., Diniz J.M.F., Luz E., Navarro-Silva M.A., Silva A.W.C., Leite S.C., Zadorosnei A.C., Musiat K.C., Veronesi E.M. and Pereira C.C. (2005). Lesões anatomopatológicas presentes na infecção por *Diectophyma renale* (Goeze, 1782) em cães domésticos (*Cannis familiaris*, Linnaeus, 1758). *Archives of Veterinary Science*, 10: pp. 95–101.
- Mace T.F. (1976). Lesions in mink (*Mustela vison*) infected with giant kidney worm. *Journal of wildlife diseases*, 12: pp. 88–92.
- Olsen O.W. (1977). *Parasitologia Animal. Editora AEDOS, Barcelona*, pp. 715–719.
- Samuel WM., Kocan A.A., Pybus M.J. and Davis J.W. (2008). Parasitic Diseases of Wild Mammals. *Iowa State*. pp. 357-364.
- Soulsby E.J.L. (1978). Helminths, Arthropods and Protozoa of Domestic Animals, sixth ed. *Baillie`re, Tindall & Cassell, London*, pp. 326–327.
- Sun T., Turnbull A., Lieverman P.H. and Sternberg S.S. (1986). Giant kidney worm (*Diectophyma renale*) infection mimicking retroperitoneal neoplasm. *American Journal of Surgical Pathology*, 10: pp. 508-512.
- Tokiwa T., Harunari T., Tanikawa T., Akao N. and Ohta N. (2011). *Diectophyma renale* (Nematoda: *Diectophymatoidea*) in the

- abdominal cavity of *Rattus norvegicus* in Japan. *Parasitology International Journal*, 60: pp. 324-326.
- Urano Z., Hadçsegawa H., Katsumata T., Toriyam K. and Aoki Y. (2001). Diotophymatid Nematode Larva Found From Human Skin with Creeping Eruption. *Journal of Parasitology*, 87: pp. 462-465.
- Verocai G.G., Measures L.N., Azevedo F.D., Correia T.R., Fernandes J.I. and Scott F.B. (2009). *Dioctophyme renale* (Goeze, 1782) in the abdominal cavity of a domestic cat from Brazil. *Veterinary Parasitology*, 161: pp. 342-344.
- Zolhavarieh SM., Norian A. and Yavari M. (2016). *Dioctophyma renale* (Goeze, 1782) Infection in a Domestic Dog from Hamedan, Western Iran. *Iran Journal Parasitol*, 11:pp. 131-135.